



OFFICE of the WAYNE COUNTY MEDICAL EXAMINER  
1300 East Warren Avenue  
Detroit, Michigan 48207  
POSTMORTEM REPORT

M. E. CASE NO. 03-04171
COUNTY OF DEATH Wayne
TOWN OF DEATH Detroit
DATE PRONOUNCED DEAD 30 Apr 2003

THIS IS TO CERTIFY THAT Carl J. Schmidt, M.D., Deputy Medical Examiner	PERFORMED A POSTMORTEM EXAMINATION ON THE BODY Tamara Green	
AT Wayne County Medical Examiner's Office	BEGINNING AT	ON 30 Apr 2003
IN THE PRESENCE OF		

AND SAID POSTMORTEM REVEALED

SUMMARY & OPINION

It is my opinion that the cause of death was multiple (3) gunshot wounds, one to the head, one through and through the face, and one through and through the left arm.

There was no evidence of close range firing on the skin surrounding the entrance wounds, but the irregularly sized, shaped, and distributed abrasions and lacerations representing pseudostippling noted on the left arm and side of the chest indicate that fire occurred through an intermediate target with fragmentation of the target and/or the bullet. The general direction of fire was from back to front and left to right. A deformed jacket and bullet were recovered from GSW A, and GSW B and GSW C were through and through.

GSW A entered the left side of the head, above and behind the ear, and passed through the left skull, the left cerebellar hemisphere, and the right temporal lobe of the brain. There was bleeding over the right side of the brain. GSW B entered the left side of the face, below and in front of the ear, and passed through the left side of the lower jaw, the floor of the mouth, and the right neck soft tissues, to exit the skin of the right side of the neck. There was aspiration of blood into both lungs, swallowed blood in the stomach, and bleeding into the muscles of the neck. GSW C entered the left outer arm and passed through the soft tissues of the left arm and shoulder, to exit the skin of the left upper chest.

There were bruises around both eyes with color changes that indicated they were inflicted prior to the gunshot wounds, and resulted from blunt trauma.

The manner of death is homicide.


(report continues on next page)

OFFICE of the WAYNE COUNTY MEDICAL EXAMINER  
1300 East Warren Avenue  
Detroit, Michigan 48207  
POSTMORTEM REPORT


M. E. CASE NO.	03-04171
NAME	Tamara Green
Page	2

Summary and Opinion (continued)

printed by: cl



Carl J. Schmidt, M.D.  
Deputy Medical Examiner  
06/02/2003



Paul Nora, M.D.  
Fellow Forensic Pathology  
06/02/2003

(report continues on next page)

OFFICE of the WAYNE COUNTY MEDICAL EXAMINER  
1300 East Warren Avenue  
Detroit, Michigan 48207  
POSTMORTEM REPORT

M. E. CASE NO.	03-04171
NAME	Tamara
	Green
Page	3

CAUSE OF DEATH:

multiple gunshot wounds

MANNER OF DEATH: HOMICIDE

NARRATIVE SUMMARY:

EXTERNAL EXAMINATION:

The body was that of a normally developed, normally nourished black female appearing about the recorded age of 26 years. The body measured 5 feet 3 inches in length and weighed 153 pounds. The body was cool, rigor mortis was partially developed, and livor mortis was present posteriorly and fixed. Clothing consisted of tan shoes, belt, shirt, and skirt, a white bra, print panties, and gray socks. The head was normocephalic and the scalp hair was black. The eyes had white sclerae, pale conjunctivae, and brown irides. The dentition was natural and in adequate repair. There were no masses discernable in the neck and the larynx was in the midline. The thorax was symmetrical and unremarkable. The abdomen was rounded. The external genitalia were those of a normal adult female. The extremities and back showed no significant deformities or other abnormalities. A 1 1/2 inch scar was present beneath each breast, as a result of breast augmentation surgery. Tattoos consisted of a design with roses around the waist and a rose with the inscription FRESH on the outer right hip.

EVIDENCE OF INJURY:

There were three gunshot wounds, as follows:

- a) There was an entrance wound on the left side of the head, 4 1/2 inches below the top of the head, 1/4 inches above the level of the left ear canal and 4 1/2 inches behind a vertical line passing through the ear canal. There was no soot or gunpowder stippling noted on the skin surrounding this wound. The wound track proceeded from this injury through the left side of the occipital bone, the left cerebellar hemisphere, and the right temporal lobe of the brain. There was a right sided subarachnoid hemorrhage. The wound track was from back to front, left to right, and slightly upward. A deformed jacket was recovered from the neck soft tissues and a slug was recovered from the brain.

(report continues on next page)

OFFICE of the WAYNE COUNTY MEDICAL EXAMINER  
1300 East Warren Avenue  
Detroit, Michigan 48207  
POSTMORTEM REPORT

M. E. CASE NO.	03-04171
NAME	Tamara
	Green

Page 4

Narrative Summary of Postmortem Examination: (continued)

- b) There was an entrance wound on the left side of the face, 6 inches below the top of the head, 3/4 inches below the level of the left ear canal and 1/2 inches in front of a vertical line passing through the ear canal. There was no soot or gunpowder stippling noted on the skin surrounding this wound. The wound track proceeded from this injury through the left side of the mandibular bone, the floor of the mouth, and the right neck soft tissues, to exit the skin of the right side of the neck, 8 1/2 inches below the top of the head and 3 inches right of the midline. There was aspiration of blood into both lungs and swallowed blood in the stomach as a result of the intraoral injuries, and hemorrhage into the cervical muscles. The wound track was from back to front, left to right, and slightly downward.
- c) There was an entrance wound on the left outer arm, 4 1/2 inches below the top of the shoulder. There was no soot or gunpowder stippling noted on the skin surrounding this wound, but there were numerous irregularly sized, shaped, and distributed small abrasions and lacerations distributed over a 12 inch diameter area of the left arm and left side of the chest (pseudostippling). The wound track proceeded from this injury through the soft tissues of the left arm and shoulder, to exit the skin of the left upper chest, 4 inches below the top of the shoulder and 2 1/2 inches left of the midline. The wound track was from back to front, left to right, and slightly upward.

There was also a 10 inch diameter area of pseudostippling to the back of the left hand and forearm, a 1/4 inch abrasion at the top of the right shoulder, and dark blue ecchymoses with green to yellow margins in both periorbital regions.

INTERNAL EXAMINATION:

An autopsy was performed utilizing the normal thoraco-abdominal and posterior coronal scalp incisions. Except for the above previously described injuries, the following internal systems were as follows:

Head:

The 1175 gm brain showed mild swelling, but was free of neoplastic lesions or infarcts. The cerebral vascular system was unremarkable.

(report continues on next page)

OFFICE of the WAYNE COUNTY MEDICAL EXAMINER  
1300 East Warren Avenue  
Detroit, Michigan 48207  
POSTMORTEM REPORT

M. E. CASE NO.	03-04171
NAME	Tamara Green
Page	5

Narrative Summary of Postmortem Examination: (continued)

Neck:

No abnormality was noted in the hyoid bone, laryngeal cartilages, trachea, or the cervical vertebral column.

Cardiovascular System:

The 225 gm heart had a normal configuration with an unremarkable epicardial surface and a moderate amount of epicardial fat. The coronary arteries had no significant atherosclerotic disease. No acute thrombi were present. Both ventricles were of normal size and their walls were of normal thickness. No focal endomyocardial lesions were present. The papillary muscles and chordae tendineae were not thickened, and the heart valves were not fibrosed. The aorta had no significant atherosclerosis. The major arteries and great veins showed normal distribution.

Respiratory System:

The larynx and trachea were unremarkable. The right and left lungs weighed 450 gm and 475 gm, respectively. There was passive congestion in the parenchyma that was accentuated with dependent lividity. No pulmonary emboli were identified.

Hepatobiliary System:

The 1150 gm liver had firm dark tan surfaces and an unremarkable parenchymal pattern. The gallbladder and biliary tracts were unremarkable.

Hemolymphatics:

The 100 gm spleen had smooth surfaces and dark purple firm pulp. There was no significant lymphadenopathy.

Alimentary System:

The tongue, esophagus, stomach, small bowel, appendix and colon were unremarkable. The lining of the stomach had an intact and unremarkable rugal pattern and the contents of the stomach consisted of approximately 50ml of blood.

Pancreas:

The pancreas showed an unremarkable tan lobulated pattern.

Endocrine System:

The thyroid gland had a normal bilobed configuration. The adrenal glands were each unremarkable with golden-yellow  
(report continues on next page)

OFFICE of the WAYNE COUNTY MEDICAL EXAMINER  
1300 East Warren Avenue  
Detroit, Michigan 48207  
POSTMORTEM REPORT

M. E. CASE NO.	03-04171
NAME	Tamara Green

Page 6

Narrative Summary of Postmortem Examination: (continued)

cortices.

Genitourinary System:

The right and left kidneys weighed 100 gm and 125 gm, respectively. Each kidney had smooth cortical surfaces, normal cortico-medullary regions, and no changes in the calyceal systems, pelves, ureters, or bladder. The non-gravid uterus was of normal size and had a smooth, glistening, tannish-pink serosal surface, and an unremarkable cervix and endometrium. The fallopian tubes and ovaries were unremarkable.

Musculoskeletal System:

Except for the above noted injuries, all the muscles and axial skeleton were free of any significant abnormalities.

DISPOSITION OF EVIDENCE:

Evidence Only

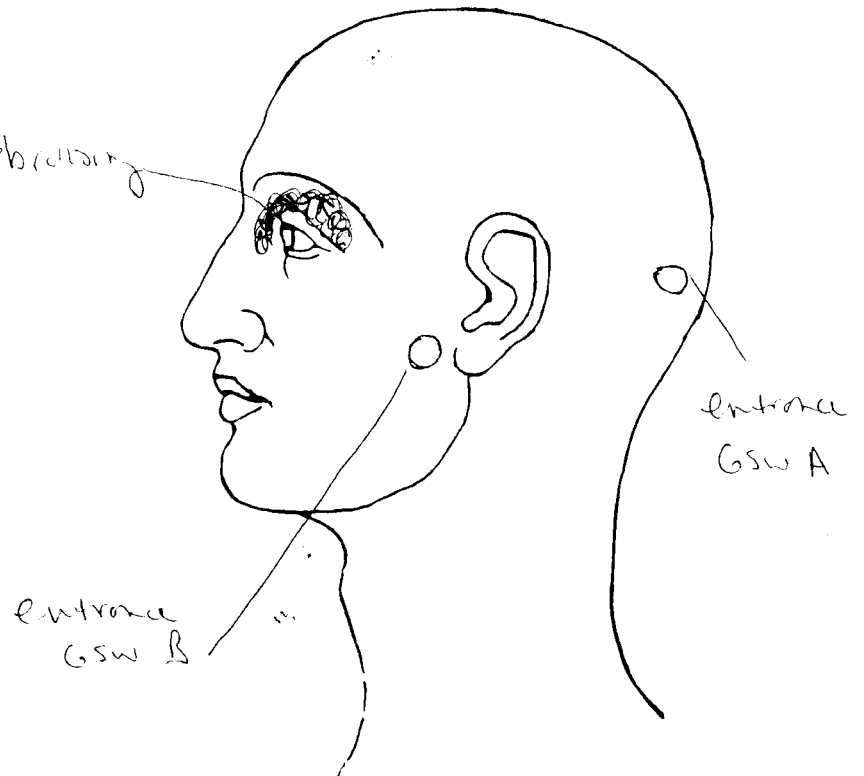
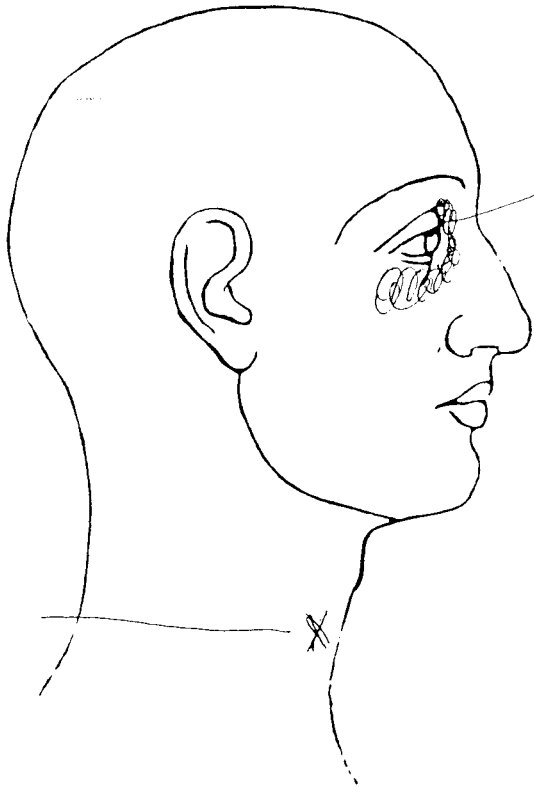
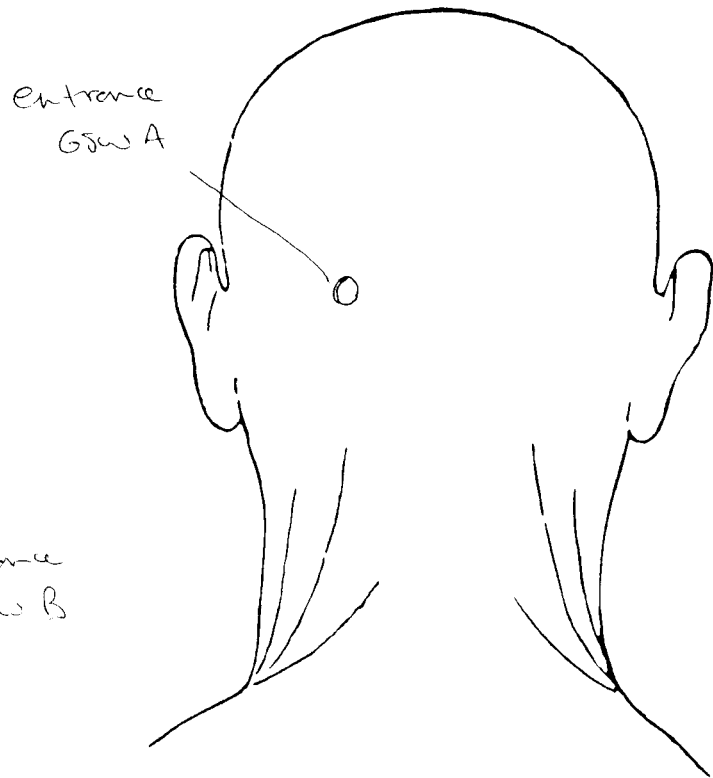
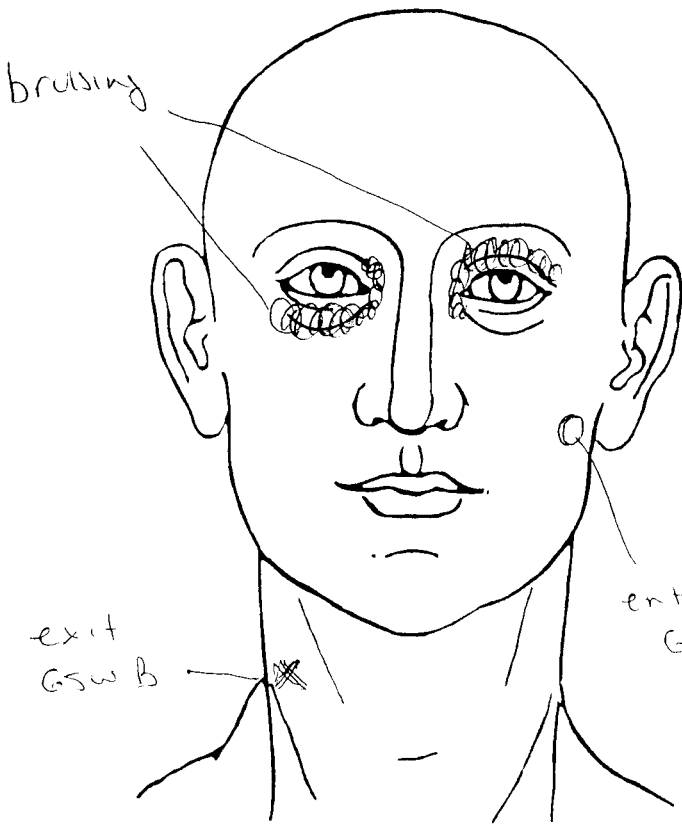
Bullet jacket from the A: 30Apr03/10:57 Fr: Carl J. Schmidt, M.D.  
neck., Bullet fragment T: 30Apr03/10:57 to: Barbara Washington  
from the brain. 30Apr03/10:58 to: MEO Storeroom  
09May03/11:30 to: Clarence L. Baker Jr.  
R: 09May03/11:31 to: Moore, David; Detroit Police Homici  
Section

(End of Report)

Tamera Green

4-30-3

03-04171



Tamera Green

4-30-3

Case # 03-04171

